

High-resolution manometry predicts the success of oesophageal bolus transport and identifies clinically important abnormalities not detected by conventional manometry

M. FOX,* G. HEBBARD,† P. JANIAC,* J. G. BRASSEUR,‡ S. GHOSH,‡ M. THUMSHIRN,* M. FRIED* & W. SCHWIZER*

*Department of Gastroenterology and Hepatology, University Hospital Zürich, Zürich, Switzerland

†Department of Gastroenterology, Royal Melbourne Hospital, Melbourne, Victoria, Australia

‡Department of Mechanical Engineering, The Pennsylvania State University, University Park, PA, USA

Abstract *Background and aims:* High-resolution manometry (HRM) is a recent development in oesophageal measurement; its value in the clinical setting remains a matter of controversy. (i) We compared the accuracy with which bolus transport could be predicted from conventional manometry and HRM. (ii) The clinical value of HRM was assessed in a series of patients with endoscopy-negative dysphagia in whom conventional investigations had been non-diagnostic. *Method:* (i) Control subjects and patients with endoscopy-negative dysphagia underwent concurrent HRM and video-fluoroscopy. Ninety-five records were reviewed using HRM with spatiotemporal plot and conventional line plots of the pressure data derived from the same recording. (ii) The HRM and notes of patients with endoscopy-negative dysphagia and abnormal bolus transport were analysed to identify additional information provided by the new technique.

Results: (i) Receiver operating characteristic analysis demonstrated that HRM predicts the presence of abnormal bolus transport more accurately than conventional manometry. (ii) HRM identified clinically important motor dysfunction not detected by manometry and radiography. These included localized disturbances of peristalsis and abnormal movement of

the lower oesophageal sphincter during oesophageal spasm.

Conclusion: The HRM predicts bolus movement more accurately than conventional manometry and identifies clinically relevant oesophageal dysfunction not detected by other investigations including conventional manometry.

Keywords *bolus transport, gastrointestinal motility, high-resolution manometry, oesophageal manometry, video-fluoroscopy.*

INTRODUCTION

The primary function of the oesophagus is the transport of food from the mouth to the stomach. Abnormal motor activity in the oesophagus can disturb bolus transport and is defined in terms of a few basic patterns seen in oesophageal manometry: abnormal sphincter relaxation, oesophageal spasm, hypertensive contractions, loss of tone and motility.¹ This classification is simple, however the neurofunctional anatomy of the oesophagus and the physiology of bolus transit have been shown to be complex.^{2, 3} The tubular oesophagus comprises several anatomic components which may be innervated by different pathways.^{2, 4, 5} The efficacy of bolus transport depends on physical properties of the swallowed material,⁶ the biomechanics of the oesophagus itself,⁶ body position,^{7, 8} and the structural limitations imposed by neighbouring thoracic structures. The complexity of this process and our inability to collect data that fully addresses this complexity may explain why in a proportion of patients presenting with dysphagia and abnormal bolus transport, the diagnosis remains obscure despite investigation using

Address for correspondence

Dr Mark Fox, Department of Gastroenterology, University Hospital Zurich, CH-8091, Zurich, Switzerland.

Tel: +41 (1) 255 1111; fax: +41 (1) 255 4083;

e-mail: markfox@doctors.org.uk

Received: 18 February 2004

Accepted for publication: 26 April 2004

conventional techniques.^{9–11} The ability of manometry with 5–8 recording channels to predict the success or failure of bolus transport is limited by poor spatial resolution. Motor abnormalities that disturb bolus transport can be limited to a short segment of the tubular oesophagus and will be missed by pressure sensors placed too far apart.^{12–15} For this reason an investigation that provides a detailed description of oesophageal motor function from the pharynx to the stomach may be required to characterize oesophageal function in health and disease.

The development of micro-manometric water-perfused assemblies¹⁶ and miniaturized solid-state pressure sensors¹⁷ has made high-resolution manometry (HRM) possible. Acquisition of pressure data from closely spaced recording channels provides a continuous recording of motor activity over the entire length of the oesophagus. Advances in computer technology allow the large data sets acquired by HRM to be analysed and presented in real time either as conventional manometric 'line plots' or as a 'spatiotemporal plot' (SPT) (also referred to as a 'contour plot'¹⁸). In addition, oesophageal video-fluoroscopy can be acquired concurrently and displayed in the same record as manometry for concurrent analysis.

In the clinical setting, the aim of oesophageal investigations is to understand the mechanical basis of symptoms, identify the disease process and guide rational treatment. Patients with endoscopy-negative dysphagia frequently have abnormal findings on oesophageal video-fluoroscopy and manometry; however with conventional manometry it is often difficult to associate dysmotility with abnormal bolus transport and symptoms.⁶ We hypothesized that HRM can predict the presence of abnormal bolus transport more often than conventional manometry. In addition, we reviewed a series of patients with endoscopy-negative dysphagia and abnormal bolus transport in whom full conventional investigation had been non-diagnostic. The HRM record and case notes of these patients were analysed to assess the diagnostic and clinical impact of additional information provided by this new technique.

SUBJECTS AND METHOD

Subjects

To compare the accuracy with which bolus transport can be predicted from conventional manometry *vs* HRM, a group of normal controls ($n = 10$), patients with dysphagia in association with reflux disease ($n = 5$) and patients with scleroderma ($n = 4$) provided a range of manometric and video-fluoroscopic findings

(normal and impaired bolus transit) to facilitate comparison and analysis. A negative pregnancy test was required from all women of childbearing potential. All participants signed an informed consent to participate in these studies, which were approved by the ethical committee of the University Hospital of Zürich.

High-resolution manometry

Manometric studies were performed after withholding medicines known to affect gastrointestinal function for at least 4 days and following a 6–12 h fast. HRM was carried out with a silicone micrometric catheter assembly (4-mm external diameter) with 21 or 32 channels spaced helically along the catheter (Dentsleeve, Wayville, South Australia, Australia). The 21-channel catheter included nine channels at 1-cm intervals across the lower oesophageal sphincters (LOS) and 10 channels at 1.5 cm in the oesophageal body plus a gastric channel 5 cm distal to the last LOS channel. The design was similar for the 32-channel catheter but with closer spacing (1.3 cm) in the oesophageal body and nine channels at 1-cm intervals across the upper oesophageal sphincters (UOS). The assembly was perfused with water using a pneumatically activated manometric pump designed and built by one of the authors (GH). Each channel was connected to an external pressure transducer (Abbott Transpac IV, Abbott Laboratories, Ontario, Canada); analogue signals from the pressure transducers were amplified using custom-built pre-amplifiers and digitized at a resolution of 16 bits and 125 Hz (PCI6033E board; National Instruments, Austin, TX, USA). The digitized signals were dealiased by filtering to 25 Hz before they were displayed in real time, stored and analysed using the Trace! software system created by one of the authors (GH).

Prior to each study, manometric lumina were initially perfused with CO₂ to remove air bubbles and the assembly was referenced under water to remove perfusion pressure offsets as previously described.¹⁹ The assembly was passed transnasally and a stationary pull-through was performed. After insertion into the stomach, the catheter was withdrawn in 1-cm steps allowing several respiratory cycles in every position. The process was continued until the most distal recording location reached the level of the LOS. The catheter was then positioned such that the section of the catheter providing the highest resolution (1 sensor cm⁻¹) traversed the LOS. A sensor distal to the LOS was used for the gastric pressure recording. For clinical studies, patients were studied in the left lateral and

seated positions. Following a 5-min baseline recording, a series of 10 swallows of 5 mL room temperature water were obtained, separated by at least 30-s intervals.

Oesophageal video manometry

Video-fluoroscopy was performed with a digital fluoroscope (MD4 Philips). Using an imaging card (IMAQ, National Instruments) and Trace! Software, images were captured at a rate of 12.5 Hz simultaneously with high-resolution manometric recording. With the patients in the left lateral position at least five swallows of low viscosity (100 cP) barium (Micropaque, Guerbet, Zürich, Switzerland) were recorded separated by at least 30-s intervals. Standard measures were taken to keep the effective radiation dose to a minimum.

Data analysis

The manometric data were reviewed using both the high-resolution data set, as well as a subset of the same data to simulate conventional manometry using a method similar to that described by Clouse *et al.*²⁰ High-resolution analysis used the data from all

channels. For the 'conventional' manometry analysis, lower resolution 'virtual catheters' were defined by censoring data from the high-resolution record to produce a series of 'virtual catheters' with sensors at intervals of 3 cm (eight channel), 4 cm (seven channel), 5 cm (six channel) and 6 cm (five channel) above the upper border of the LOS. For both the HRM and lower resolution 'virtual catheters', LOS pressure was defined as the highest pressure from six channels spanning the LOS (a 5-cm 'virtual sleeve'). All pressure measurements were referenced to gastric pressure.

Pressure resolution

The pressure resolution acquired by each 'virtual catheter' was compared with HRM. The pressure data from each 'virtual catheter' were interpolated to produce an SPT as for the HRM data (described below). For the purposes of this analysis, coordinates were defined by their position in time (x-axis) and space (y-axis) on the SPT (rather than by channel). The pressure at each x, y coordinate was derived for the HRM pressure data and for each of the virtual catheters. The correlations between the pressure value at each x, y coordinate on the SPT derived from the high-resolution and each lower-resolution data set were calculated.

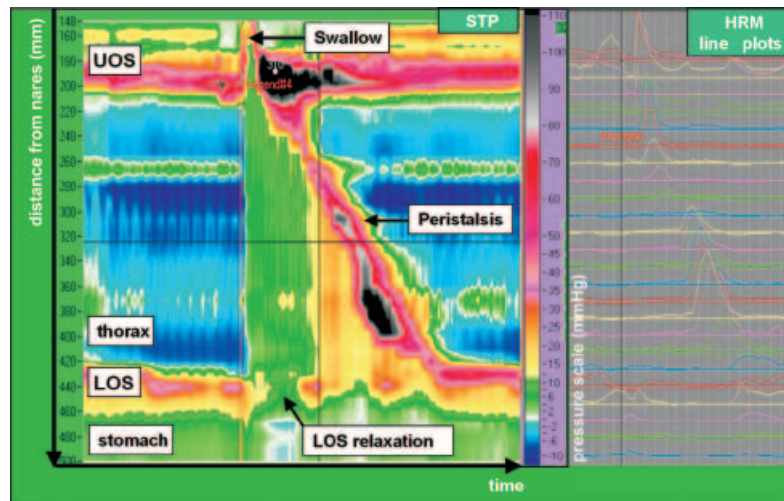


Figure 1 Normal 32-channel high-resolution manometry (HRM) of 10 mL water swallows. HRM spatiotemporal plot (STP) depicts the direction and force of pressure activity in the oesophagus from the pharynx to the stomach. The STP presents the same information as presented in the line plots, however the large volume of data is easier to appreciate in a single image than multiple line plots. Time is on the x-axis and distance from the nares is on the y-axis. Each pressure is assigned a colour (legend adjacent to figure). The normal physiology of oesophageal function is clearly demonstrated including the synchronous relaxation of the upper oesophageal sphincter (UOS) and lower oesophageal sphincters (LOS), the pressure trough between the proximal and middle tubular oesophagus and the increasing pressure and duration of the peristaltic wave as it passes distally. In addition, subtle but functionally important pressure events are demonstrated clearly. These include the 'common cavity' pressure rise after the water swallow and the build up of the oesophago-gastric pressure gradient as peristalsis approaches the LOS.

Analysis of conventional and high-resolution manometry

For HRM pressure data from all channels was interpolated creating a two-dimensional SPT (Fig. 1). In this plot, each pressure value was assigned a colour, here optimized to maximize pressure resolution between 0 and 40 mmHg. The pressure data could be analysed in detail by moving a cursor over the SPT to evaluate pressure changes over time, or variation in pressure along the length of the oesophagus at different times (i.e. pressure gradient). By selectively censoring pressure data, a seven-channel 'virtual catheter' was derived from the HRM data and this data was presented as conventional 'line plots'. LOS resting pressure was recorded by a 'virtual sleeve' positioned across the sphincter for both analyses. The high-resolution STP and conventional line plots were reviewed independently for each individual swallow by two physicians (WS, MT) and classified on the basis of established criteria.¹

Prediction of bolus transport

To compare the potential of conventional vs HRM to identify abnormal bolus transport, a receiver operating characteristic (ROC) analysis was performed. For the purposes of this analysis, the 'gold-standard' assessment of oesophageal function was considered to be bolus transport assessed by video-fluoroscopy. Two physicians (WS, MT) blinded to manometric and clinical findings reviewed images from each individual barium swallow. Swallows were ranked in terms of barium clearance from the oesophagus according to a prospectively agreed classification scheme from normal-to-complete failure of bolus transport (a seven-grade Likert-scale detailed in Fig. 2).

The same physicians reviewed manometric data from the conventional and high-resolution data sets separately and in a blinded manner from the fluoroscopic data. For each data set, a prediction was made whether the motor activity was compatible with normal bolus transport. Disagreements were resolved by consensus, but always blinded to all data other than that under evaluation. The actual success of bolus transport was then compared with the prediction of success from both conventional and HRM. This was carried out sequentially taking each rank (from normal to complete failure of bolus transport) as a diagnostic cut-off; thus the accuracy of the predictions based on manometric findings was assessed for every level of success of bolus transport.

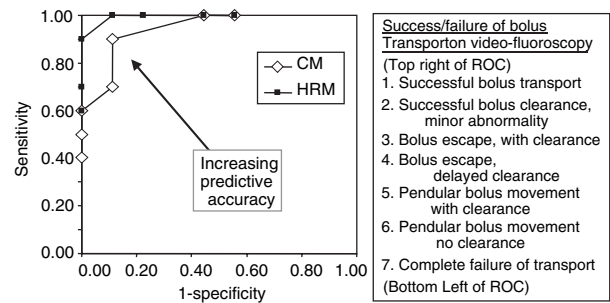


Figure 2 Receiver operating characteristic (ROC) analysis.

The accuracy of conventional and high resolution manometry for the prediction of bolus transport is displayed at seven potential 'levels' of success/failure of bolus transport on video-fluoroscopy: bolus escape indicates that part of the bolus remained in the oesophagus after the initial swallow, pendular movement of the bolus indicates that the whole bolus remained in the oesophagus after the initial swallow. Both conventional manometry (CM) and HRM were accurate at predicting both complete success and failure of bolus transport. HRM was more accurate than CM at predicting disturbed bolus transport at mild-moderate levels of transit abnormality. HRM had equal or greater sensitivity and specificity at every level. The larger area under the ROC curve indicates that HRM predicts bolus transport more accurately than conventional manometry.²¹

RESULTS

Pressure resolution

Comparing the pressure resolution of the STP derived from HRM with each of the lower resolution 'virtual catheters', the mean correlation coefficient for pressure at any x, y coordinate on the plot decreased progressively from 1.00 with 21-channel HRM to 0.72 (range 0.65–0.85) for conventional manometry with five channels. The five-channel pressure resolution was lower than other 'virtual catheters' ($P < 0.05$), however the pressure resolution of the seven or eight-channel analyses was similar [0.85 (0.76–0.95) vs 0.89 (0.81–0.97), $P = \text{ns}$]. The seven-channel 'virtual catheter' (five intra-oesophageal sensors at 4-cm intervals, 'virtual sleeve' and gastric reference) was used as 'conventional' manometry for further comparisons with HRM.

Reproducibility of manometry and video-fluoroscopy data

Ninety-five barium swallows with concurrent oesophageal video-fluoroscopy and manometry were analysed. There was excellent agreement between the reviewers for the assessment of bolus transport by

video-fluoroscopy with only two recordings requiring consensus. Interobserver agreement for the classification of individual swallows was similar for conventional (77%) and high-resolution (75%) manometry. Disagreements concerned the presence or absence of a non-specific motor dysfunction (NSMD). This was of little importance for further analysis because these swallows were generally compatible with bolus transport.

Comparing the (consensus) classification of individual swallows made by conventional manometry and HRM, the two reviewers agreed in 59% of their individual classifications. Swallows categorized as NSMD by conventional manometry were not infrequently labelled as normal by HRM and vice versa. Of more functional and clinical importance, swallows classified as hypomotility ($n = 15$) or oesophageal spasm ($n = 11$) by HRM were classified as normal or with NSMD by conventional manometry. No comparison was made for LOS pressure and function because the same 'virtual sleeve' was applied for both analyses.

Prediction of abnormal bolus transport

Both conventional manometry and HRM were accurate at predicting both normal bolus transport and severe transit abnormalities. HRM was more accurate than seven-channel (conventional) manometry at predicting the presence of disturbed bolus transport at mild-moderate levels of transit abnormality.

The ROC analysis demonstrated that for every 'level' of success/failure of bolus transport on video-fluoroscopy (i.e. potential diagnostic cut-off), the sensitivity and specificity with which HRM predicted the success/failure of bolus transport was equal or higher than for conventional manometry (Fig. 2). The area under the ROC curve was greater for HRM than conventional manometry indicating greater accuracy of prediction.²¹ For example, if bolus escape with delayed clearance is taken as the diagnostic cut-off HRM successfully predicted abnormal bolus transport with a sensitivity of 90% at a specificity level of 100%. For conventional manometry, a sensitivity of 70% was associated with a specificity of 89%.

Case series

The University Hospital of Zürich is a tertiary referral centre. The HRM is the standard investigation of oesophageal motility in our Department. Approximately 200 patients are referred for such diagnostics each year, about 50 of whom have endoscopy-negative dysphagia.

In this retrospective case series, the HRM of patients with endoscopy-negative dysphagia were reviewed. Prior to referral, most patients had undergone full investigations, without receiving a definitive diagnosis. In certain cases, careful inspection of the conventional manometry showed non-specific motor abnormalities, however the significance of these was not appreciated at referral. No patient had a history of oesophageal injury, surgery, concurrent medical disorders or intake of medications known to affect gastrointestinal motility. The HRM STP was analysed to identify additional information not provided by other tests. The impact of these findings on diagnosis and patient management was assessed. To facilitate comparison, HRM with STP is displayed together with conventional line plots derived from the same data set.

Localized abnormality of peristalsis 1 A 34-year-old white man presented with a long history of dysphagia for solids, regurgitation of unaltered food and intermittent bolus obstruction. His sister had received treatment for similar symptoms at another hospital without definitive diagnosis. Upper gastrointestinal endoscopy and pH studies were normal. Video-fluoroscopy revealed bolus escape in the mid-oesophagus without dilatation or structural abnormality, and computed tomography demonstrated no extramural lesions. Conventional manometry showed only non-specific motor abnormalities (reported as normal) and the patient was referred for further investigation. HRM was performed. No abnormality could be seen on the conventional line plots, however the STP revealed a widened proximal transition zone (pressure trough)^{3, 18, 22} between the proximal and the mid-segments of the tubular oesophagus. Simultaneous contractions were occasionally seen in the mid-oesophagus, but peristalsis in the distal oesophagus was preserved. The position of the transition zone coincided with the level of bolus escape on concurrent video-fluoroscopy. The patient was pleased to have a clear explanation of his symptoms; however management with bougie dilatation and prokinetic medication brought only limited improvement in his symptoms (Fig. 3).

Localized abnormality of peristalsis 2 A 40-year-old Portuguese woman had a long history of chest pain radiating into the back. These pains occurred only while eating and were associated with occasional bolus obstruction. Chest radiography demonstrated a right-sided aortic arch. Endoscopy showed no abnormality. Video-fluoroscopy revealed bolus escape in the mid-oesophagus but no dilatation or obstruction. HRM was

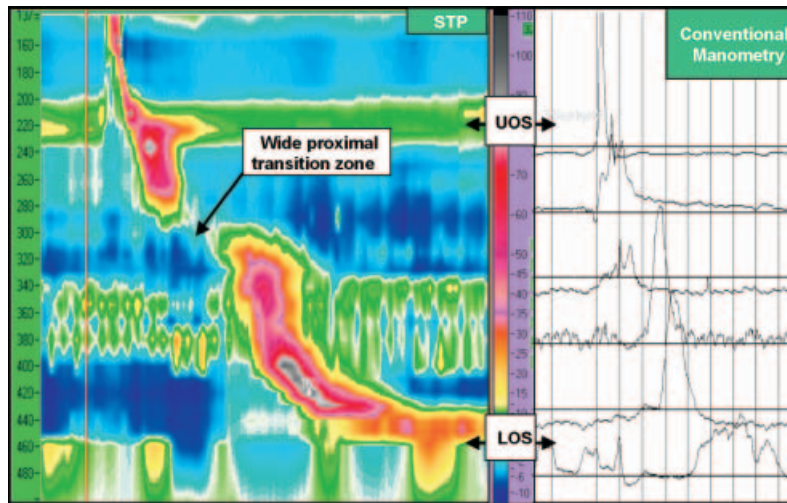


Figure 3 Localized abnormality of peristalsis (wide proximal transition zone). The 32-channel HRM from a patient with dysphagia and regurgitation. There is a wide proximal transition zone (pressure trough) between the proximal (striated muscle) and distal (smooth muscle) oesophagus. As discussed in references,^{3, 22} the coordination between the proximal and distal compartments of the oesophagus is lost. Bolus escape was seen in this region on concurrent video-fluoroscopy.

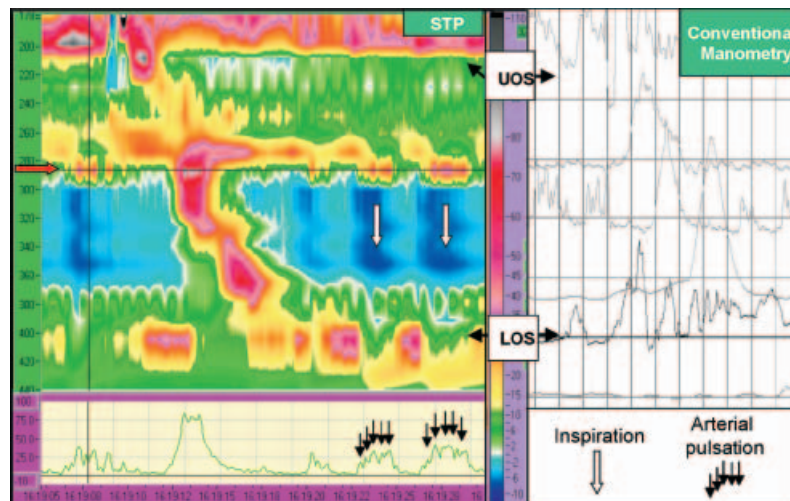


Figure 4 Localized abnormality of peristalsis (arteria lusoria). The 32-channel HRM from a patient with dysphagia and chest pain after swallowing. A band of raised pressure is seen 280 mm distal from the nares (red arrow). Peristalsis is interrupted by a segmental, simultaneous contraction extending to about 30 mm below this level for about 2 cms. Above this band, an area of raised ‘common cavity’ pressure is seen, suggesting fluid retention proximal to the obstruction. This was confirmed on concurrent video-fluoroscopy. The box below the spatiotemporal plot displays pressure in time at the location of the red arrow mid-oesophagus. Note the arterial pulsation (black arrows) superimposed on slow respiratory changes (white arrow). This abnormality corresponds to the position of an arteria lusoria diagnosed at CT angiography.

performed. A band of raised pressure on the conventional line plots was considered to be a commonly observed artefact produced by impingement of the aortic arch on the oesophagus. However the HRM STP demonstrated that this band of pressure interrupted peristalsis and that segmental contractions were present in the mid-oesophagus. Above this level, intraluminal pressure was raised relative to the distal oesophagus. Pressure in this region was uniform, suggesting a ‘common cavity’ and fluid retention proximal

to the lesion. Concurrent video-fluoroscopy confirmed bolus escape and retention at this level. On the basis of these investigations, CT angiography was requested and revealed an arteria lusoria²³ arising from the right-sided aortic arch at the level of the pressure band passing posterior to the oesophagus. The patient declined surgical management (Fig. 4).

Localized abnormality of peristalsis 3 A 54-year-old white woman presented with a long history of mild

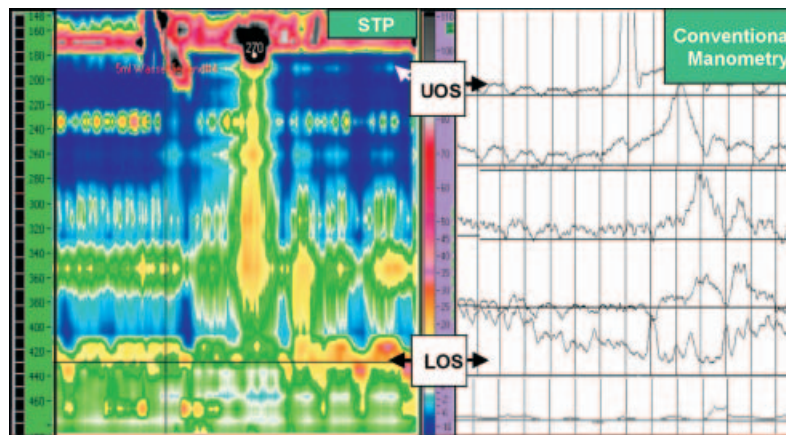


Figure 5 Localized abnormality of peristalsis (segmental contractions). The 32-channel HRM from a patient with mild reflux symptoms and occasional regurgitation. The spatiotemporal plot reveals hypotensive, segmental contractions in the mid- and distal-oesophagus. The lower oesophageal sphincter (LOS) appears normal. The conventional line plots are not normal, however the extent and nature of this motility disorder cannot be fully appreciated (the patient was diagnosed with a mild, NSMD prior to referral). Bolus escape and proximal movement of barium was observed concurrent with the simultaneous contractions on concurrent video-fluoroscopy.

reflux symptoms, dysphagia for solids and regurgitation of food. There was a partial response to acid suppression. Upper gastrointestinal endoscopy was normal. Video-fluoroscopy revealed no structural abnormality, however oesophageal clearance was inefficient and there was occasional proximal movement of barium bolus. Conventional manometry was reported as showing mild NSMD. The patient was referred for further investigation and consideration of anti-reflux surgery. HRM was performed. The conventional line plots showed non-specific motor abnormalities, however HRM clearly revealed simultaneous contractions in the mid- and distal-oesophagus. The pH studies were only mildly abnormal (DeMeester Score 21.0). As a consequence of these findings, anti-reflux surgery was considered inappropriate, the patient reported symptomatic benefit with high dose acid suppression and nitrate medications (Fig. 5).

Oesophageal spasm with pseudorelaxation of the LOS A 32-year-old woman presented with a 6-month history of dysphagia with frequent episodes of chest pain lasting several seconds after swallowing. Uncoordinated contractions in the distal oesophagus were observed on endoscopy. Video-fluoroscopy revealed oesophageal spasm but no prolonged retention of the bolus. HRM was performed. Conventional line plots and HRM revealed simultaneous hypertensive contractions (>300 mmHg) of the tubular oesophagus and raised basal LOS pressure (50 mmHg). Relaxation of the LOS appeared to be normal using the 'virtual

sleeve' sensor, however HRM demonstrated incomplete relaxation of the LOS (nadir pressure 35 mmHg, 30% relaxation). Extensive axial movement of the LOS relative to the manometry catheter during oesophageal spasm caused a spurious appearance of LOS relaxation. Dramatic shortening of the tubular oesophagus meant that the virtual sleeve sensor was in the stomach during oesophageal spasms and therefore recorded what appeared to be normal LOS relaxation (pseudorelaxation).²⁴ A diagnosis of vigorous achalasia was made and botulinum toxin treatment of the LOS and distal oesophagus was applied.²⁵ The patient made an immediate symptomatic recovery with only mild persistent dysphagia to solids and no chest pain. Definitive treatment with Heller myotomy with proximal extension to include the distal oesophagus is planned (Fig. 6).

DISCUSSION

Oesophageal manometry with five to eight pressure sensors is the standard investigation for endoscopy-negative dysphagia and other conditions associated with oesophageal dysfunction.¹ However diagnoses based on conventional manometry are often interpretive, based as much on the clinical presentation as the pressure recordings. The association between conventional manometric findings and symptoms is often poor,¹⁰ and the pathological basis of symptoms remains unclear in a significant minority of patients.^{9, 11} This may be because dysphagia is more closely related to

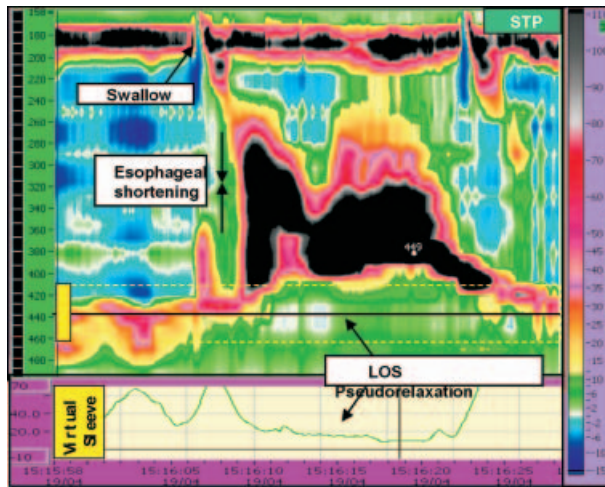


Figure 6 Abnormal movement of the LOS. The 32-channel HRM from a patient with dysphagia, regurgitation and chest pain after swallowing. There is incomplete LOS relaxation and powerful oesophageal spasm causing marked shortening of the oesophageal body diagnostic of vigorous achalasia. The box below the spatiotemporal plot displays pressure recorded from a 5 cm 'virtual sleeve'. The LOS spuriously appears to relax (pseudorelaxation) during spasms when the 'virtual sleeve' moves into the stomach as the LOS moves proximally abnormally far.

disturbed bolus transport than oesophageal motor activity *per se*. High-resolution manometry is a natural evolution from conventional manometry. Spacing pressure channels closely at <2-cm intervals provides detailed pressure information sufficient to detect segmental abnormalities of motor function,^{12–15} and to assess the pressure gradients that dictate bolus movement.⁶ We hypothesised that HRM should predict the success or failure of bolus transport more accurately than conventional manometry. In addition, we considered clinical cases in which HRM identified the physiological basis of endoscopy-negative dysphagia not detected by other investigations.

It can be difficult to demonstrate the advantages of new techniques such as HRM against established investigations such as conventional manometry (the current reference standard¹). 'Final diagnosis' based on full investigation and clinical course has been used to compare the techniques,^{20, 26} however the outcome in such studies is not independent of the investigations being tested. We addressed this issue by using bolus transport as an independent assessment of oesophageal function. The ability of physicians (experienced with both techniques) to predict the success of bolus transport from HRM and conventional manometry was then compared. To ensure a direct comparison

between the techniques, both pressure records were derived from the same swallow. The 'conventional' manometry record was obtained by censoring data from selected channels to produce a 'virtual catheter' (as described by Clouse *et al.*²⁰); however to address criticisms made of the original approach,²⁷ the spacing of channels on our 'virtual catheter' was higher than previous studies (4-cm intervals) and a 'virtual sleeve' was introduced. Validation studies demonstrated that using fewer channels significantly reduced pressure resolution of a STP derived from this data, whereas increasing the number of channels to provide 3 cm separation had only minor effects.

We recruited healthy controls and patients with endoscopy-negative dysphagia with a history of either reflux disease or scleroderma. As expected, these subjects displayed a range of manometric and radiographic findings that facilitated comparison and analysis. In this diverse group, the HRM STP enabled us to predict the success or failure of bolus transport more accurately than with conventional manometry. The ROC analysis demonstrated that HRM increased both sensitivity and specificity of these predictions,²¹ indicating that the physicians analysing the data were able to distinguish important manometric abnormalities likely to disturb bolus transport from unimportant manometric abnormalities of no functional importance. As disturbed bolus transport is an important cause of oesophageal symptoms, this finding suggests that HRM can improve diagnostic accuracy in the clinical setting.

In particular, swallows with segmental hypotensive contractions or spasm evident on HRM were often classified as normal or with NSMD (consistent with bolus transport) by conventional manometry. These findings indicate that HRM can accurately predict the success of bolus transport. However, manometry provides only indirect evidence of the relationship between symptoms, motor dysfunction and bolus transport. Formal evidence for a causal relationship would require a comparison of the HRM and video-fluoroscopy records from patients with and without dysphagia. Multiple intraluminal impedance manometry (measurement of electrical impedance between points) is another method that can indicate movement of liquid and air in the gastrointestinal tract. Similar to HRM, the advantage of this technique is in the lack of radiation and thus the ability to sample many swallows. Unlike HRM, the analysis and interpretation of impedance data remains difficult and although impedance manometry is sensitive to experimental conditions²⁸ more experience is required before it can be applied in routine clinical practice.

Direct evidence that HRM provides more clinically relevant information than conventional manometry was provided by the case studies. For each of the patients with endoscopy-negative dysphagia and abnormal bolus transport, the HRM STP identified subtle functionally important manometric abnormalities that had not been detected with conventional manometry. In three cases, HRM revealed segmental manometric abnormalities. These included a widened transition zone between the proximal and mid-oesophagus, a focal band of pressure caused by extrinsic obstruction of the oesophagus, and simultaneous contractions occurring in discrete segments of the oesophagus. All these abnormalities were either not detected or not appreciated using conventional manometry because recording channels separated by 4 cm failed to provide the necessary spatial resolution. In the final case, the diagnosis of vigorous achalasia was missed by conventional manometry, whereas incomplete relaxation of the LOS was clearly seen on HRM. Movement of the LOS relative to the manometry catheter caused this discrepancy. Dramatic oesophageal shortening left the virtual sleeve sensor in the stomach during oesophageal spasms producing what appeared to be normal LOS relaxation (pseudorelaxation).²⁴

It must be emphasized that these patients were highly selected, having been extensively investigated previously without a diagnosis being made. The motor abnormalities demonstrated were clinically significant but the HRM diagnosis did not always fit the conventional classification of motility disorders.¹ Nevertheless, HRM did provide a pathological basis for functional disturbance and symptoms, and its findings guided clinical management. Even when HRM findings did not lead to specific treatment, a definitive explanation for the presence of symptoms prevented further investigations or inappropriate treatments, and was often itself therapeutic.

Based on 5 years experience with HRM in Zürich University Hospital, we estimate that around 10% of patients under investigation for endoscopy-negative dysphagia have non-diagnostic conventional manometry but receive a definitive diagnosis by HRM. About half of these have focal (often hypotensive), simultaneous contractions; the others have abnormalities of the LOS. This is consistent with findings from a series of 212 unselected clinical patients reported by Clouse *et al.*²⁰ In this large group of patients there was manometric disagreement in 12% and diagnostic disagreement in 5% (10 patients) between HRM and a limited five-channel (conventional) analysis of the same data (agreement appears lower in the current study because the comparison was based on single

swallows not a full investigation). Compared against 'final diagnosis', the conventional analysis failed to identify six achalasia patients and was less effective in segregating hypotensive and aperistaltic motility disorders. In only one patient was the HRM diagnosis changed at follow-up. Measurement of the pressure gradient across the sphincter had high sensitivity and specificity for achalasia, and was superior to point-pressure measurements of LOS relaxation.²⁹

In clinical practice, HRM has few limitations and many advantages. The presence of recording channels from the pharynx to the stomach removes the need for the time-consuming pull-through procedure and facilitates the positioning of the assembly. No sleeve sensor is required and the movement and interaction of the diaphragmatic and intrinsic LOS (e.g. in the presence of a hiatus hernia) can be observed. Moreover, in patients with a weak or unstable LOS, HRM aids the placement of pH probes.²⁰ Although a large amount of data is collected, the STP provides a convenient and compact method of representing the data. The human brain is more attuned to recognition of images than interpreting abstract information,³⁰ and the HRM STP provides a more intuitive means of assessing the oesophageal pressure activity than multiple line plots. This facilitates the detection of abnormal motor activity,^{20, 26} and for routine clinical studies data analysis proceeds simultaneously with data acquisition.

In conclusion, this paper demonstrates that HRM increases the accuracy with which the success (or failure) of bolus transport can be predicted from manometric data. The case series illustrates that HRM can provide physiologically and clinically relevant information in patients with endoscopy-negative dysphagia in whom standard investigations do not provide a definitive diagnosis. We conclude that HRM is an important advance in the assessment of oesophageal function that is likely to bring benefits in clinical practice.

ACKNOWLEDGMENTS

We are grateful to the assistance of Denise Schilter and Anita Gehrig for their assistance in the gastrointestinal motility laboratory. Mark Fox and Patrick Janiak were supported by grants from the Swiss National Science Foundation. James Brasseur and Sudip Ghosh were supported under NIH grant R01-DK56033. Parts of this work were presented in abstract form at the Annual Meeting of the American Gastroenterological Association May 2000 and at the Meeting of the European Society of Neurogastroenterology and Motility October 2002.

REFERENCES

- 1 Spechler SJ, Castell DO. Classification of oesophageal motility abnormalities. *Gut* 2001; **49**: 145–51.
- 2 Clouse R, Staiano A. Topography of the esophageal peristaltic pressure wave. *Am J Physiol Gastrointest Liver Physiol* 1991; **261**: G677–84.
- 3 Li M, Brasseur JG, Dodds WJ. Analyses of normal and abnormal esophageal transport using computer simulations. *Am J Physiol* 1994; **266**: G525–43.
- 4 Weinstock L, Clouse R. Esophageal physiology: normal and abnormal motor function. *Am J Gastroenterol* 1987; **82**: 399–405.
- 5 Diamant N. Physiology of esophageal motor function. *Gastroenterol Clin North Am* 1989; **18**: 179–94.
- 6 Brasseur J, Dodds W. Interpretation of intraluminal manometric measurements in terms of swallowing mechanics. *Dysphagia* 1991; **6**: 100–19.
- 7 Ren J, Massey BT, Dodds WJ *et al.* Determinants of intrabolus pressure during esophageal peristaltic bolus transport. *Am J Physiol* 1993; **264**: G407–13.
- 8 Poudroux P, Shi G, Tatum RP, Kahrilas PJ. Esophageal solid bolus transit: studies using concurrent videofluoroscopy and manometry. *Am J Gastroenterol* 1999; **94**: 1457–63.
- 9 Ott DJ, Richter JE, Chen YM, Wu WC, Gelfand DW, Castell DO. Esophageal radiography and manometry: correlation in 172 patients with dysphagia. *AJR Am J Roentgenol* 1987; **149**: 307–11.
- 10 Kahrilas PJ, Clouse RE, Hogan WJ. American Gastroenterological Association technical review on the clinical use of esophageal manometry. *Gastroenterology* 1994; **107**: 1865–84.
- 11 Lundquist A, Olsson R, Ekberg O. Clinical and radiologic evaluation reveals high prevalence of abnormalities in young adults with dysphagia. *Dysphagia* 1998; **13**: 202–7.
- 12 Freidin N, Mittal RK, Traube M, McCallum RW. Segmental high amplitude peristaltic contractions in the distal esophagus. *Am J Gastroenterol* 1989; **84**: 619–23.
- 13 Traube M, Peterson J, Siskind BN, McCallum RW. ‘Segmental aperistalsis’ of the esophagus: a cause of chest pain and dysphagia. *Am J Gastroenterol* 1988; **83**: 1381–5.
- 14 Massey BT, Dodds WJ, Hogan WJ, Brasseur JG, Helm JF. Abnormal esophageal motility. An analysis of concurrent radiographic and manometric findings. *Gastroenterology* 1991; **101**: 344–54.
- 15 Hirano I, Tatum RP, Shi G, Sang Q, Joehl RJ, Kahrilas PJ. Manometric heterogeneity in patients with idiopathic achalasia. *Gastroenterology* 2001; **120**: 789–98.
- 16 Chen WH, Omari TI, Holloway RH, Checklin H, Dent J. A comparison of micromanometric and standard manometric techniques for recording of oesophageal motility. *Neurogastroenterol Motil* 1998; **10**: 253–62.
- 17 Clouse RE, Parks T, Haroian LR, Zakko SF. Development and clinical validation of a solid-state high-resolution pressure measurement system for simplified and consistent esophageal manometry. *Am J Gastroenterol* 2003; **98**: S32–3.
- 18 Clouse RE, Staiano A. Topography of the esophageal peristaltic pressure wave. *Am J Physiol* 1991; **261**: G677–84.
- 19 Hebbard G, Brasseur J. High resolution perfusion manometry using an underwater reference. *Neurogastroenterol Motil* 1999.
- 20 Clouse RE, Staiano A, Alrakawi A, Haroian L. Application of topographical methods to clinical esophageal manometry. *Am J Gastroenterol* 2000; **95**: 2720–30.
- 21 Hanley JA, McNeil BJ. A method of comparing the areas under receiver operating characteristic curves derived from the same cases. *Radiology* 1983; **148**: 839–43.
- 22 Ghosh SK, Janiak PO, Schwizer W *et al.* Existence and coordination of distinct contraction waves above and below the esophageal transition zone. *Neurogastroenterol Motil* 2002; **14**: 582 (abstract).
- 23 De Luca L, Bergman JJ, Tytgat GN, Fockens P. EUS imaging of the arteria lusoria: case series and review. *Gastrointest Endosc* 2000; **52**: 670–3.
- 24 Goldenberg SP, Burrell M, Fette GG, Vos C, Traube M. Classic and vigorous achalasia: a comparison of manometric, radiographic, and clinical findings. *Gastroenterology* 1991; **101**: 743–8.
- 25 Katzka DA, Castell DO. Use of botulinum toxin as a diagnostic/therapeutic trial to help clarify indication for definitive therapy in patients with achalasia. *Am J Gastroenterol* 1999; **94**: 637–42.
- 26 Clouse RE, Prakash C. Topographic esophageal manometry: an emerging clinical and investigative approach. *Dig Dis* 2000; **18**: 64–74.
- 27 Holloway RH. Topographical clinical esophageal manometry: a better mousetrap or manometric overkill? *Am J Gastroenterol* 2000; **95**: 2677–9.
- 28 Nguyen HN, Silny J, Matern S. Multiple intraluminal electrical impedancemetry for recording of upper gastrointestinal motility: current results and further implications. *Am J Gastroenterol* 1999; **94**: 306–17.
- 29 Staiano A, Clouse RE. Detection of incomplete lower esophageal sphincter relaxation with conventional point-pressure sensors. *Am J Gastroenterol* 2001; **96**: 3258–67.
- 30 Mamassian P, Landy MS. Interaction of visual prior constraints. *Vision Res* 2001; **41**: 2653–68.